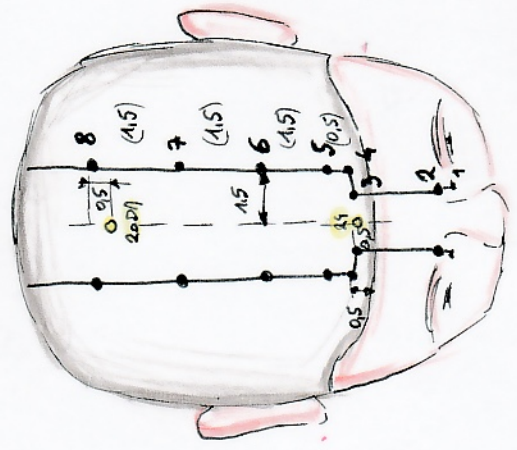
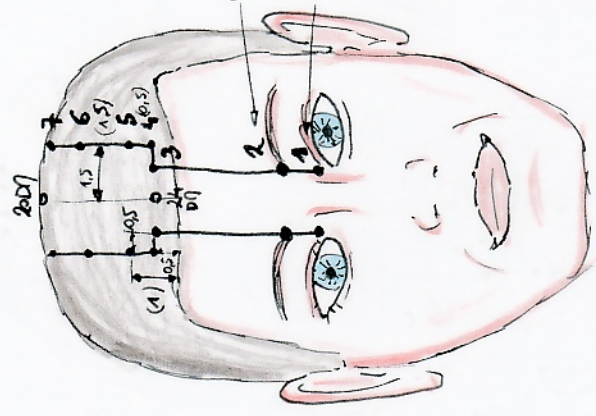


VESSIE



protrubérance occipitale
 bord ext du trapèze (os Ischior)
 11 → 21 bord inf. de l'apophyse épineuse de D.

